

Superior Peroneal Retinaculum Tear in a High School Athlete: A Case Report

Gaetano Sanchioli, MS, ATC

University of Pittsburgh Medical Center Health Systems' Center for Sports Medicine and Keystone Oaks High School, Pittsburgh, PA

Objective: To present the case of an 18-year-old football player who chose conservative treatment for a superior peroneal retinaculum tear and to review alternatives.

Background: Superior peroneal retinaculum tears are often mistaken for lateral ankle instability. These tears often do not heal readily by themselves and must be identified so that proper treatment can begin.

Differential Diagnosis: Superior peroneal retinaculum tear, peroneal subluxation, peroneal retinacular avulsion, snapping ankle.

Treatment: This athlete chose conservative treatment, which may have cost him 4 weeks and the chance to return to his senior season. Surgical treatment can reduce recovery time.

Uniqueness: This case history presents an athlete who was thought to have a grade II lateral ankle sprain. After weeks of rehabilitation, pain and effusion diminished, but the athlete was still unable to perform any functional activity without symptoms of pain and catching.

Conclusions: Making the correct clinical diagnosis and understanding the time frame involved in rehabilitative versus surgical treatment are necessary to return the athlete to play in a timely manner.

Key Words: fibrocartilage ridge, peroneal tunnel compression test

Injury to the superior peroneal retinaculum (SPR) is, as first noted by Blanquet in 1875, a relatively infrequent injury.¹ The injury has been most commonly seen in snow skiing, ice hockey, football, and tennis, respectively. The SPR is integral to the stability and function of the peroneal muscles and tendons, particularly the peroneus longus and brevis. The peroneus longus and brevis are important dynamic stabilizers of the ankle but also contribute to plantar flexion and eversion.

The peroneus longus and brevis tendons extend in a common sheath distally and posteriorly around the lateral malleolus to the base of the fifth metatarsal, where the brevis inserts. The peroneus longus then extends to the first metatarsophalangeal joint. The superior and inferior peroneal retinacula secure these tendons as they make the turn around the malleolus, aided by a fibrocartilage ridge to help deepen the groove.² This enables the malleolus to act as a pulley, increasing the tension of the muscles. If the ridge is too shallow, peroneal tendons can sublux or dislocate more readily.^{3,4} The peroneus tertius, although it has a common origin with the longus and brevis muscles, runs anterior to the lateral malleolus, and, therefore, SPR tears do not usually affect it.

Injury to the SPR is often accompanied by injury to the posterior talofibular ligament or the calcaneofibular ligament. These lateral ligaments are taut when the ankle is dorsiflexed and act as static ankle stabilizers.³ The calcaneofibular and posterior talofibular ligaments and the SPR tend to have a near-parallel alignment, which may suggest a reason for the coexistence of SPR injury, lateral ankle instability, and, in the

worst cases, splits in the peroneus brevis tendon.³ Chronic calcaneovalgus may predispose an athlete to SPR tears, perhaps because passive eversion of the calcaneus compromises the tension of the peroneal tendons.¹ However, the injury most commonly occurs with forceful, passive dorsiflexion, which produces a reflex contraction of the peroneals and a tightening of the tendons against the SPR. Evaluation of cadaver ankles has shown 5 variations in the SPR.⁵ Structurally, these ligament types can be bandlike or bifurcating. Each has a common origin from the fibular ridge; however, their insertion sites can include bony, fibrous, and soft tissue attachments. It is uncertain whether 1 of these ligament types predisposes certain people to SPR tears.

CASE PRESENTATION

In the fourth game of the season, an 18-year-old football running back was tackled from behind while entering the end zone. He seemed to relax as he crossed the goal line, and the defender, while making a desperation tackle, landed directly on the posterior aspect of the athlete's leg, forcefully hyperdorsiflexing and everting his ankle (Figure 1). The athlete limped from the field and described hearing a "pop" while being tackled. Initially, the pain and effusion were generalized over the entire ankle, and his strength was significantly diminished. Acutely, the injury appeared to be a grade II lateral ankle sprain. Unable to complete functional tests, the athlete was removed from the contest, and cryotherapy was applied immediately.

Upon reevaluation the next day, the effusion had decreased modestly, and the athlete was exquisitely tender on the posterior aspect of the fibula, superior to the malleolus. However, he did not have any significant pain when the ankle was palpated

Address correspondence to Gaetano Sanchioli, MS, ATC, UPMC Health System Center for Sports Medicine, 4601 Baum Boulevard, Pittsburgh, PA 15213. E-mail address: SANCHIOLIGJ@MSX.UPMC.EDU




Figure 1. A photograph of the actual injury shows contact distal to the knee as the athlete's foot hits the ground, thus hyperdorsiflexing and everting the ankle.

anteriorly or medially. Circumducting his ankle created an audible “pop,” and the tendons could be felt subluxing anteriorly on palpation. Three days postinjury, the athlete was seen for evaluation by a physician, who diagnosed a peroneal retinaculum tear and recommended magnetic resonance imaging (MRI). He felt that rehabilitation might not be a viable option to allow the athlete to return before the season ended.

The athlete was referred to an orthopaedic surgeon for a second evaluation. The posterior tibiofibular ligament was identified on the MRI as being injured, possibly including the SPR. The orthopaedic surgeon felt the MRI was inconclusive, and, because no subluxation of the peroneal tendons could be reproduced in the office, surgery was not needed.

The athlete sought a third opinion from a foot and ankle subspecialist. In this physician's opinion, the tendon was “snapping within the groove.” He was less confident in surgical treatment unless the tendon was clearly subluxing anteriorly over the top of the retinaculum. All 3 physicians agreed that the MRI showed effusion lateral to the fibula and superior to the malleolus, which indicated irritation to the lateral compartment (Figure 2).

On the suggestion of the foot and ankle subspecialist, the athlete decided to postpone surgery in favor of rehabilitating for 6 weeks. At that time, if no improvement had been made, surgery could be done.

Initially, the goal of treatment was to minimize the effusion and regain full range of motion through the use of heating modalities, ultrasound, elevation, massage, and stretching. Also, at this time, open chain strength exercises and non-weightbearing Biomechanical Ankle Platform System exercises (BAPS, Alimed Inc, Dedham, MA) were instituted. Throughout this time, the athlete was walking, crutch assisted, but he refused to wear a walking boot. As his strength increased and he was able to perform normal daily activities, we started closed chain exercises, including leg presses, lunges, stair climber exercises, and full weightbearing BAPS with platform loading. Within a week, the athlete was rated 5/5 on the manual muscle testing score for all ranges of motion. However, snapping occurred with plantar flexion and eversion, and the tendons needed to be stabilized with tape so that

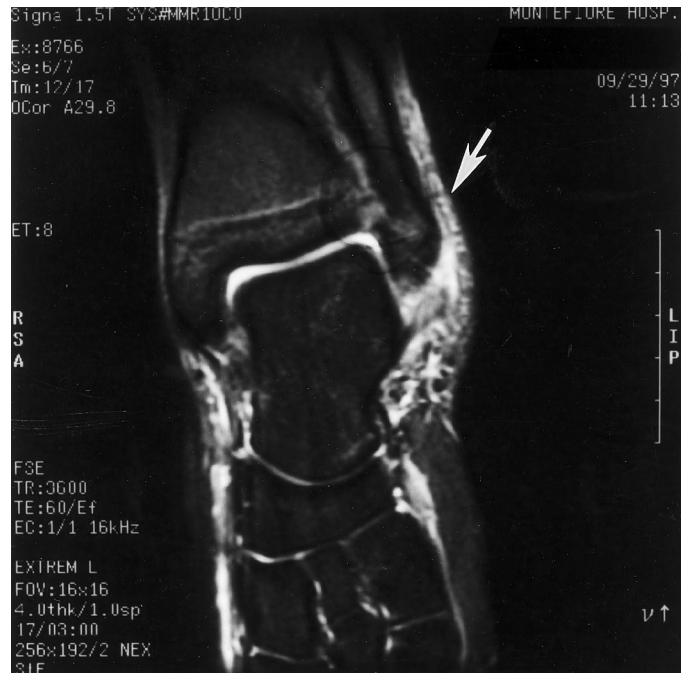

Figure 2. MRI taken 3 days after the injury does not conclusively show any damage to the peroneal retinaculum. However, effusion lateral to the fibula is seen.

functional exercise could be performed. The athlete was taped with a felt pad posterior and inferior to the lateral malleolus and the foot in a dorsiflexed position. He was able to exercise on a stair climber and use a BAPS board up to level 4 with minimal discomfort and snapping of the tendons.

He progressed to a functional exercise program on the field consisting of cone drills specific to his position. However, when asked to perform the simplest functional drills, he was able to reach only 50% capacity without limping, discomfort, and snapping of the tendons. He was unable to move laterally or backward due to discomfort and instability, and crossover movements were nearly impossible to perform.

After the 6 weeks of rehabilitation, the regular season was in its last week, the athlete was not able to participate in the playoffs, and he did not return to the physician. Due to frustration with his progress and continued pain, accompanied by snapping and catching of the tendons, he started rehabilitation on his own consisting of general strength and conditioning and did not return to the training room. The athlete attempted to return to play basketball 8 weeks after the injury, but participated in only 3 games. He claimed his ankle was not 100% and declined further treatment. At 12 weeks, normal use of the ankle had returned, and he was able to play baseball in the spring without incident.

DISCUSSION

A torn SPR allows the peroneal tendons to become hypermobile and sublux anteriorly, adversely affecting their static and dynamic functions. Patients typically exhibit audible and palpable popping and snapping, the result of recurrent dislocation or subluxation of these tendons over the lateral malleolus.⁴ This sensation can be reproduced with normal daily activities, especially walking stairs (both up and down), and clinically by the peroneal tunnel compression test.² The weakness resulting from the loss of tension is totally debilitating.

Any athlete who relies on quick, forceful lateral movements or split-second changes in direction will be severely affected by this injury.

SPR tears can be classified into 3 categories. In grade I tears, occurring 51% of the time, the retinaculum is raised from the periosteum, possibly with a tear in the sheath. Grade II tears, which occur in 33% of the cases, also include a tearing away from the fibrocartilage ridge that serves as the attachment point for the SPR; this may appear on x-ray as a cloudy area posterior to the fibula and superior to the lateral malleolus. Grade III tears occur 16% of the time, when the SPR avulses from the fibrocartilage ridge and pulls off a fleck of bone.¹ Longitudinal splits in the peroneus brevis tendon may occur with any of these injuries, but most commonly occur with grade III tears.^{2,3}

Differentiating SPR tears from inversion ankle sprains is important for the athletic trainer. An SPR tear often presents with lateral pain and swelling on examination. The talar tilt and anterior drawer tests are usually positive for pain, thereby giving the appearance of an inversion ankle sprain. Few SPR sprains are diagnosed radiologically or on MRI, whereas types I and II may not cause signs or symptoms and, therefore, may go unrecognized.⁵ Clinically, 3 tests can be used to assess the integrity of the SPR. The peroneal tunnel compression test² is done by exerting pressure against the tightening tendons at the level of the SPR, causing pain in the presence of an SPR tear or peroneal tendon split. The ankle circumduction test is a reliable test for all types of retinaculum tears.⁶ This is performed by palpating the peroneal tendons at the level of the SPR and asking the athlete to circumduct the ankle. A third test is performed by actively and passively everting the dorsiflexed ankle.⁷ Pain and tendon subluxation constitute positive tests.

In this case study, it is important to note that the rehabilitation was successful in helping this athlete regain his full strength. However, full strength was not accompanied by full function. Full functional capacity did not return until 10 to 12 weeks later. Surgical intervention for a torn SPR has proved to be both easy and reliable,⁷ although few studies have been done to show which are the best procedures.⁸ Many of the current surgeries performed to correct a torn SPR are variations of the early procedures done by Ellis Jones. The 3 basic components of these surgeries are to reconstruct the SPR, deepen the peroneal groove, and reroute the tendons.^{1,7} In a study by Poll and Duijfjes,⁹ 15 patients with SPR tears were monitored.⁹ Nine patients had grade II and III tears. Three of these patients elected to have surgery immediately, whereas the remaining 6 chose conservative treatment. Six patients had grade I tears, all of whom started rehabilitation. Within 10 weeks, 3 of these patients chose surgical intervention. Three remained in rehabilitation, and only 1 reported a full recovery.

Of the 12 surgical patients, postoperatively 11 reported being free from repeated dislocations, and 1 patient was lost during the follow-up.

I am not suggesting that surgery is the only option. As the study by Poll & Duijfjes⁹ and this case suggest, if rehabilitation is chosen as an alternative to surgery, the result is questionable and may not occur in a reasonable time frame for return to competition. For example, this athlete tested at 100% clinically but could perform at only 50% functionally. With regard to the time frame, an extra 4 weeks of playing time to a professional, collegiate, or high school athlete may affect the athlete's livelihood and the chance of securing a contract or a scholarship. In this patient, 6 to 8 weeks for full recovery after surgery, as opposed to 10 to 12 weeks of rehabilitation, may have permitted this player to participate during the playoff portion of the football season.

However, all the normal risks of surgery are present, including secondary infection, other complications, and failed surgery. For these reasons, the method of intervention, the time frame involved, and the needs of the athlete must be considered by the athlete, parents, athletic trainers, coach, and physician.

ACKNOWLEDGMENTS

I thank Dr. David Stone for his guidance in the writing and organization of this case history.

REFERENCES

1. Arrowsmith SR, Fleming LL, Allman FL. Traumatic dislocations of the peroneal tendons. *Am J Sports Med.* 1983;11:142-146.
2. Sobel M, Geppert MJ, Olson EJ, Bohne WHO, Arnoczky SP. The dynamics of peroneus brevis tendon splits: a proposed mechanism, technique of diagnosis, and classification of injury. *Foot Ankle.* 1992;13:413-422.
3. Geppert MJ, Sobel M, Bohne WH. Lateral ankle instability as a cause of superior peroneal retinacular laxity: an anatomic and biomechanical study of cadaveric feet. *Foot Ankle.* 1993;14:330-334.
4. Cwinn AA, Marx JA. Peroneal retinaculum injury: an unusual cause of ankle pain. *Ann Emerg Med.* 1987;16:105-107.
5. Eckert WR, Davis EA Jr. Acute rupture of the peroneal retinaculum. *J Bone Joint Surg Am.* 1976;58:670-672.
6. Lohnes JH, Garrett WE Jr, Monto RR. Soccer. In: Fu FH, Stone DA, eds. *Sports Injuries: Mechanisms, Prevention, and Treatment.* Baltimore, MD: William & Wilkins; 1994:603-624.
7. Kollias SL, Ferkel RD. Fibular grooving for recurrent peroneal tendon subluxation. *Am J Sports Med.* 1997;25:329-335.
8. Sobel M, Warren RF, Brouman S. Lateral ankle instability associated with dislocation of the peroneal tendon treated by the Chrisman-Snook procedure: a case report and literature review. *Am J Sports Med.* 1990;18:539-543.
9. Poll RG, Duijfjes F. The treatment of recurrent dislocation of the peroneal tendons. *J Bone Joint Surg Br.* 1984;66:98-100.