Journal of Athletic Training 2006;41(3):341–344
© by the National Athletic Trainers' Association, Inc
www.journalofathletictraining.org

Central Cord Syndrome in a High School Wrestler: A Case Report

Valerie Rich; Elizabeth McCaslin

Steadman Hawkins Sports Medicine Clinic, Vail, CO

Valerie Rich, PhD, ATC, CSCS, and Elizabeth McCaslin, ATC, contributed to conception and design; acquisition of the data; and drafting, critical revision, and final approval of the article.

Address correspondence to Valerie Rich, PhD, ATC, CSCS, University of South Florida, 4202 East Fowler Avenue, PED 214, Tampa, FL 33620. Address e-mail to valtrainer@aol.com.

Objective: To alert athletic trainers to the importance of recognizing the signs and symptoms of central cord syndrome.

Background: A 15-year-old high school wrestler was found lying supine on the mat after sustaining a hyperextension injury to his neck while drilling during practice, complaining of numbness, tingling, and a burning sensation in all 4 extremities. Touching the extremities elicited an extreme burning sensation. After in-line stabilization of the cervical spine was performed, palpation of the spinous processes elicited tenderness and an increase in pain. Six weeks before the injury, the athlete had experienced forced lateral flexion of the cervical spine during a match, resulting in an episode of bilateral numbness and burning in his arms. On evaluation by the athletic trainer, symptoms were limited to the right hand, and brachial plexus neurapraxia was diagnosed.

Differential Diagnosis: Central cord syndrome, brachial plexus injury, cervical spine injury, burning hands syndrome, Brown-Séquard syndrome, anterior cord syndrome.

Treatment: Upon assessment, the athlete's cervical spine was immobilized until emergency medical services arrived and applied a cervical collar. Radiographs taken at the hospital revealed a congenital fusion of C6-7. Magnetic resonance imaging and computed tomography showed evidence of stenosis, a herniated disc at C3-4, and a central cord injury. He was admitted to the hospital for observation and was placed on a corticosteroid protocol. At approximately 1 week after the injury, the athlete underwent a cervical decompression and fusion at C3-4. Subsequently, he underwent extensive rehabilitation and has had some persistent neck stiffness. The athlete is no longer allowed to participate in contact sports as a result of the presence of stenosis at multiple levels.

Uniqueness: Central cord syndrome is typically seen in an older population with cervical spondylosis and rarely occurs in young adolescents. However, this athlete sustained 2 central cord injuries, 1 mild and 1 severe, in less than 6 weeks' time.

Conclusions: The original injury sustained by the wrestler was thought to be a brachial plexus injury but, in fact, was a mild central cord injury. Central cord syndrome was not suspected in the original injury because the athlete's complaint was of unilateral numbness. With the second injury, the central cord injury was more severe. Proper recognition, assessment, and handling of this situation were crucial in providing optimal care to this athlete.

Key Words: spinal cord injury, athletic injury, neurologic injury

Immediate recognition and management of a spinal cord injury is a crucial factor in providing optimal care and the best long-term prognosis. Cervical spine injuries infrequently occur in athletes and can often be very confusing and difficult to assess. In the United States, approximately 10 000 spinal cord injuries are reported each year, only 10% of which occur during organized athletic events. Spinal cord injuries constitute a small percentage of sport-related injuries overall, only 2% to 3%.[1]

The distribution of injuries within the population is bimodal. A high incidence of reported cervical spine injuries occurs in individuals between the ages of 15 and 24 years and in individuals older than 50 years. These injuries are seen more frequently in men than in women and more frequently in an African American population than in whites.[2] The most common causes of spinal cord injuries include falling from heights (19%–30%), motor vehicle accidents (42%–56%), gunshots (12%–21%), and athletic activity (6%–7%).[2,3]

The cervical spine anatomy makes little sense, considering that it is one of the most delicate structures of the body and yet has little protection. This leaves the area susceptible to injury, especially in high-risk contact sports. The cervical spine has 4 protective factors, which include curvature (lordosis) that acts as a shock absorber, musculature to provide strength, ligaments to resist excessive motion, and bones to protect the spinal cord.[4] The cervical spine can be injured in the following ways: hyperflexion injury (forcing the neck forward), hyperextension (forcing the neck backward), lateral flexion (forcing the neck to the side), axial loading (compression of the neck from a hit on top of the head), and rotational forces (twisting of the neck).[1,5] Cervical spinal stenosis can also predispose an athlete to cervical spine injury.[6]

First described by Schneider in 1954, central cord syndrome (CCS) is a specific type of incomplete spinal cord lesion that is not typically found in the athletic population but generally occurs in older individuals with preexisting cervical spine conditions such as arthritis or spondylosis.[7–9] The result of a hyperextension injury or anterior compression of the cervical spine, this injury produces complete tetraplegia (paralysis of all 4 extremities), loss of motor (muscle) control, and usually a greater loss of function in the upper extremities than in the lower extremities. Sensory loss in the extremities varies, typ-

ically occurring below the level of injury, and a loss of bladder function is noted.[7,8]

Confusing CCS with other acute spinal cord injuries, such as Brown-Séquard syndrome, a brachial plexus injury, burning hands syndrome, anterior cord syndrome, or spinal cord injury without radiologic abnormality (SCIWORA), is possible because of some shared characteristics. If the initial diagnosis is incorrect, the athlete's care may be jeopardized. However, a careful initial assessment will identify CCS. Rapid but accurate diagnosis is essential.

As stated before, severe cervical spine injuries rarely occur in athletes, and the likelihood of CCS presenting in a young athlete is even less. However, athletic trainers should be prepared to handle the situation appropriately and accurately assess the athlete's condition. The following case report describes a 15-year-old high school wrestler who sustained a mild CCS in a wrestling match and continued to wrestle. He then sustained a severe CCS 6 weeks later. The patient's presentation in the first injury was not typical of a central cord injury, whereas the subsequent injury resulted in what would be considered a typical presentation of CCS. This case clearly illuminates the importance of understanding the different cervical spine conditions and how they present on initial assessment.

CASE REPORT

A 15-year-old high school wrestler competed in a wrestling match and was thrown by his opponent. The athlete landed with his neck laterally flexed to the left and his right shoulder depressed, resulting in right shoulder pain and paresthesias into the right hand. An athletic trainer (AT) performed the initial assessment, which revealed no tenderness to touch over the cervical spine or either shoulder. The wrestler was able to move both upper extremities through a full range of motion, and his shoulder and neck strength was good. The numbness and tingling resolved, and he continued to wrestle in the match. The patient was reevaluated in the athletic training room at the end of the competition. He complained of some residual numbness and tingling into the right hand. Again, the cervical spine was nontender. He also exhibited good motor strength in both upper and lower extremities. The patient was monitored closely by an AT, and his signs and symptoms resolved after 2 days. His initial assessment was documented as a brachial plexus neurapraxia because his signs and symptoms presented unilaterally and the mechanism of injury was forced lateral flexion of the cervical spine.

Six weeks later, at wrestling practice, the athlete landed on his head, sustained a hyperextension injury, and immediately fell limp to the ground. He had no loss of consciousness. The athlete was lying on his back motionless, with a considerable amount of pain and obviously scared. Upon examination, he complained of numbness and tingling in all 4 extremities. Touching all extremities elicited an extreme burning sensation. The cervical spine was immediately immobilized and emergency medical services activated. With stabilization maintained, the cervical spine was palpated and tenderness was elicited over the spinous processes. Palpation also increased the patient's pain in both arms. When the ambulance arrived, the patient was still complaining of numbness and tingling in all 4 extremities and was notably weak in motor function, especially in the upper extremities. The patient was placed in a cervical collar, secured to a spine board, and transferred to the emergency room for further evaluation.

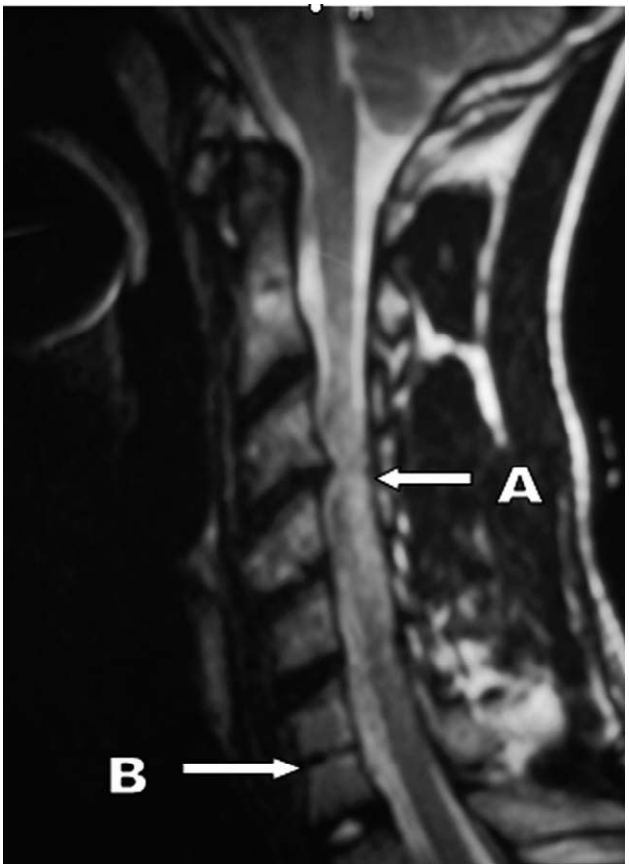

Figure 1. Sagittal magnetic resonance imaging scan shows disc herniation at C3-4 (arrow A) and congenital fusion at C6-7 (arrow B).

A team physician met the patient in the emergency room. Radiographs revealed a congenital fusion of C6-7. Magnetic resonance imaging (MRI) and computed tomography showed evidence of cervical spinal stenosis. The MRI and computed tomography also showed a herniation of the C3-4 vertebral disk and revealed evidence of CCS (Figure 1). The patient was admitted to the hospital's intensive care unit for observation and was placed on a corticosteroid protocol. He remained in the hospital for 2 days and was then released to go home in a Philadelphia cervical collar. Upon discharge, the patient still complained of residual weakness and paresthesias in the upper extremities. He had no complaints of paresthesias or weakness in the lower extremities.

The patient returned 4 days later to the sports medicine clinic for a preoperative visit with the orthopaedic physician. During that visit, the patient was asked several questions regarding this injury. He revealed that approximately 6 weeks earlier, during a match, he had paresthesias in all 4 extremities for about 5 seconds (this finding was not mentioned to the AT at the time of injury). The physician determined that the individual had sustained a mild CCS at that time. The patient's physical examination at the preoperative visit showed biceps brachii and triceps brachii weakness in both arms. Lower extremity reflexes were graded as normal but brisk bilaterally. Other neurologic tests were negative. The orthopaedic physician's plan was to perform an anterior cervical decompression and fusion using iliac crest bone graft and plate. This proce-

Figure 2. Postoperative radiograph showing the anterior cervical decompression and fusion.

dure was necessary because of the neck instability and spinal cord injury.

The next day, the patient underwent successful surgery, and he remained in the hospital for 3 days. At his 1-week follow-up, the patient stated that his shoulder paresthesias had improved dramatically. He had better strength in both upper extremities and was able to perform activities of daily living using his arms. Radiographs showed excellent position of the plate and graft (Figure 2). By the 6-week follow-up, the wrestler stated that all of his symptoms had resolved. On examination, the incisions were completely healed, and range of motion of the cervical spine was 50% of normal (normal flexion is 80°–90°, extension is 70°, lateral flexion is 20°–45°, and rotation is 70°–90°).[10] His strength had fully recovered in both triceps muscles, but he had slight residual weakness in both biceps. Radiographs revealed excellent positioning of the hardware and consolidation at the fusion.

Three months after surgery, the patient returned to the office for a final checkup with minimal complaints. He stated that he had returned to lifting weights and was playing basketball (''shooting around'') with no problems. The patient told the physician that when he flexed his neck, he experienced numbness and tingling that radiated down the spine and into the posterior aspect of both legs, lasting for 2 to 3 seconds. The physical examination revealed that the patient had regained most of his range of motion in the neck, strength was fully recovered, and special tests were negative. The physician was concerned about the symptoms elicited with cervical flexion and therefore ordered a repeat MRI.

The MRI revealed mild stenosis at other levels in the cervical spine, in addition to the congenital fusion at C6-7 and some degeneration at the level above the fusion. The surgery site itself had healed completely. Discussion arose at the end of the visit regarding the patient's being allowed to participate in wrestling, football, skiing, and snowboarding. The physician strongly discouraged this participation because of the inherent risk of injury and because the patient still had narrowing of the spinal canal (stenosis) at other levels of the spine. The physician recommended participation in noncontact sports such as tennis, bowling, and running. At this point, the patient has not returned to any contact sports and is completely asymptomatic.

DISCUSSION

Currently, very few cases of CCS have been reported in athletes. In 1984, the first case was described in a 17-year-old body surfer, who sustained a hyperextension injury to the cervical spine.[11] Radiographic examination revealed that the athlete had congenital spinal stenosis and a Klippel-Feil deformity (fusion) at C2-3. Recently, another case of CCS was reported in a 21-year-old collegiate football player who also sustained a cervical hyperextension injury.[8] Similarly, this athlete had congenital spinal stenosis at the C3-4 level. In addition, this athlete presented with a paracentral disk protrusion at C3-4. This athlete made a full recovery at 6 months postinjury and was allowed to participate in noncontact sports only.

One of the contributing factors to CCS in athletes is cervical spine stenosis. Spinal stenosis is defined as a narrowing of the spinal canal and has been a topic of debate among sports medicine and spine surgeons for many years.[6] The Torg ratio, first introduced in the 1980s, has been used to determine evidence of stenosis on radiographs. However, preseason screening with the Torg ratio has not been a reliable tool in determining cervical spine injury risk in asymptomatic athletes.[12] The debate has more recently focused on athletes with spinal stenosis and recommendations for return to play. In a recent literature review, Eddy et al[12] discussed determinations for return to play in specific cervical spine injuries. The authors concluded that standard guidelines for the management of cervical spine injuries and return to play are lacking. Morganti et al[13] evaluated the return-to-play decisions of sports medicine and spine physicians who each evaluated 10 case studies of athletes with various cervical spine injuries. Again, agreement was lacking regarding determination of return to play after cervical spine injury. More research is needed to create a standardized set of guidelines regarding risk factors for cervical spine injuries and determination of return to play after cervical spine injury.

The differential diagnosis for CCS includes Brown-Séquard syndrome, brachial plexus injury, anterior cord syndrome, burning hands syndrome, and SCIWORA. The AT must be able to recognize the signs and symptoms of each condition. Brown-Séquard syndrome is an injury to the spinal cord on 1 side, resulting in loss of motor and sensory function on that side and loss of pain and temperature sensation on the other side. Brown-Séquard syndrome usually occurs as a result of penetrating trauma or cervical fracture. The overall prognosis is good, with approximately 90% of patients being able to walk and regain bowel and bladder control.[2]

Brachial plexus injuries are commonly seen in athletes and result from a stretching or compression of the brachial plexus. This injury, which results in a unilateral, transient burning sen-

sation, numbness and tingling, and radiating pain from the shoulder down to the hand, is often difficult to distinguish from a spinal cord injury. In some cases, motor function may be impaired. Typically the symptoms only last 30 seconds to several minutes, but they can last up to several days in severe cases.[14] The treatment of a brachial plexus injury is conservative, consisting usually of monitoring the signs and symptoms closely.

Anterior cord syndrome is an injury to the anterior two thirds of the spinal cord that results in a complete loss of motor and sensory function. This condition usually results from a hyperflexion injury, a fracture-dislocation, or a burst fracture. Loss of motor function is greater in the legs than the arms, which is the opposite of what occurs in CCS.[15] The prognosis is the worst of all these syndromes. If no progress is noted within the first 24 hours of care, it is unlikely that advances in recovery will be made. The overall rate for individuals to return to normal daily functioning is less than 15%.[2]

Burning hands syndrome is characterized by burning sensations in the hands and is usually associated with a cervical fracture or dislocation. This condition is a mild variant of CCS, causing weakness in the arms and hands. Some individuals may sustain this injury without any cervical spine abnormalities. In this case, signs and symptoms usually resolve within 24 hours, and patients are allowed to return to competition once asymptomatic.[1]

Lastly, SCIWORA is a common injury associated with the pediatric population. The large size of the head and the increased mobility of the cervical spine in conjunction with ligamentous laxity can leave the cervical spine susceptible to injury.[16] This injury typically results from a hyperextension injury or a fracture through the cartilaginous plate of the cervical spine (not detected on radiographs). Anterior displacement of the cervical vertebrae may occur and is termed a pseudosubluxation. The outcome associated with this injury is determined by the patient's neurologic status on initial evaluation.[17]

CONCLUSIONS

Central cord syndrome is not a common injury in athletes and, in fact, few cases have been reported. Our patient sustained 2 central cord injuries in 6 weeks (1 mild and 1 severe injury). One of the lessons learned from this case is that a thorough history should be obtained. The initial injury was documented as a brachial plexus injury because of unilateral complaints. However, further questioning revealed that the patient's signs and symptoms were bilateral and that the initial injury was a mild CCS. Appropriate management and recognition of the signs and symptoms of CCS are of utmost importance. Cervical spine injury protocol should be followed and emergency medical services activated when necessary in suspected CCS. Patients complaining of bilateral numbness and tingling should be referred immediately to an orthopaedic spine surgeon or neurosurgeon for physical examination and radiologic evaluation. After full recovery, return to play should be discussed by the surgeon, parents, athlete, and AT and all risk factors addressed. We hope that this case serves as an example to clearly illustrate the importance of understanding the different cervical spine conditions and how they present on initial assessment. Proper recognition, assessment, and handling of this situation were crucial in providing this athlete with optimal care and a favorable long-term prognosis.

ACKNOWLEDGMENTS

We thank Eric Strauch, PA-C, and Dr Donald Corenman for their help and expertise with this case.

REFERENCES

1. Maroon JC, Bailes JE. Athletes with cervical spine injury. *Spine.* 1996; 21:2294–2299.
2. Slucky AV, Eismont FJ. Treatment of acute injury of the cervical spine. *Instr Course Lect.* 1995;44:67–80.
3. National Spinal Cord Injury Statistical Center. Spinal Cord Information Network: Facts and Figures at a Glance, 2003. University of Alabama at Birmingham. Available at: http://www.makoa.org/nscia/fact02.html. Accessed December 19, 2005.
4. Wieder BH. Cervical spine injuries in athletes. *CNI Review.* 2000;11(1). Available at: http://www.thecni.org/reviews/11-1-p03-wieder.htm. Accessed December 19, 2005.
5. Newey ML, Sen PK, Fraser RD. The long-term outcome after central cord syndrome: a study of the natural history. *J Bone Joint Surg Br.* 2000; 82:851–855.
6. Torg J, Guille JT, Jaffe S. Injuries to the cervical spine in American football players. *J Bone Joint Surg Am.* 2002;84:112–122.
7. Alpert MJ. Central cord syndrome. Available at: http://www.emedicine.com/pmr/topic22.htm. Accessed March 9, 2004.
8. Finnoff JT, Mildenberger D, Cassidy CD. Central cord syndrome in a football player with congenital spinal stenosis: a case report. *Am J Sports Med.* 2004;32:516–521.
9. Walsh K, Lee S. Cervical spine injuries. In: Starkey C, Johnson G, eds. *Athletic Training and Sports Medicine.* 4th ed. Boston, MA: Jones and Bartlett; 2005:518–550.
10. Magee DJ. *Orthopedic Physical Assessment.* 4th ed. New York, NY: WB Saunders; 2002:121–181.
11. Epstein NE, Epstein JA, Zilkha A. Traumatic myelopathy in a seventeen-year-old child with cervical spinal stenosis (without fracture or dislocation) and a C2-C3 Klippel-Feil fusion: a case report. *Spine.* 1984;9:344–347.
12. Eddy D, Congeni J, Loud K. A review of spine injuries and return to play. *Clin J Sport Med.* 2005;15:453–458.
13. Morganti C, Sweeney CA, Albanese SA, Burak C, Hosea T, Connolly PJ. Return to play after cervical spine injury. *Spine.* 2001;26:1131–1136.
14. Prentice WE. *Arnheim's Principles of Athletic Training: A Competency-Based Approach.* 11th ed. Boston, MA: McGraw-Hill; 2003:809–818.
15. Merriam WF, Taylor TK, Ruff SJ, McPhail MJ. A reappraisal of acute traumatic central cord syndrome. *J Bone Joint Surg Br.* 1986;68:708–713.
16. Kothari P, Freeman B, Grevitt M, Kerslake R. Injury to the spinal cord without radiological abnormality (SCIWORA) in adults. *J Bone Joint Surg Br.* 2000;82:1034–1037.
17. Pang D, Pollack IF. Spinal cord injury without radiographic abnormality in children: the SCIWORA syndrome. *J Trauma.* 1989;29:654–664.